

Phase I study of hepatic intralesional rose bengal disodium, an autolytic immunotherapy, in metastatic neuroendocrine neoplasms

1106P

2021 ESMO Annual meeting
16-21 September

Timothy J Price^{1,2,3}, Gabby Cehic^{1,3}, Eric Wachter⁴, Ian Kirkwood^{3,5}, Jessica Reid^{1,2}, Ruben Sebben¹, Anas Alawawdeh¹, Mark McGregor¹, Dominic Rodrigues⁴, Susan Neuhaus³, Guy Maddern^{1,2,3}

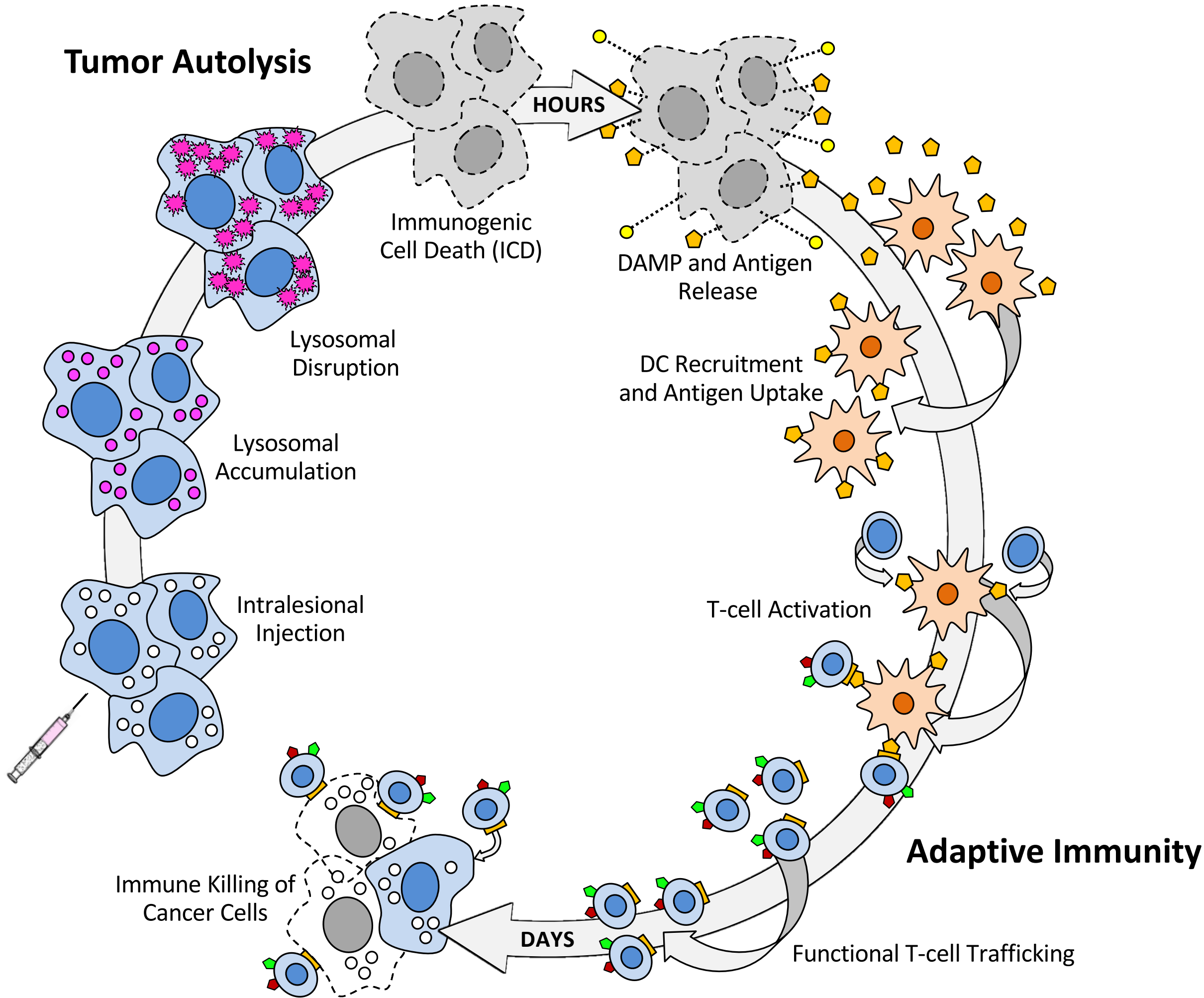
¹ The Queen Elizabeth Hospital, Adelaide, SA AUS; ² Basil Hetzel Institute for Translational Health Research, Adelaide, SA AUS; ³ University of Adelaide, Adelaide, SA AUS; ⁴ Provectus Biopharmaceuticals, Inc, Knoxville, TN USA; ⁵ Royal Adelaide Hospital, Adelaide, SA AUS

For additional information: wachter@pvct.com
or Timothy.Price@sa.gov.au

Background and Methods

Metastatic neuroendocrine neoplasms (mNEN) originating in the gastrointestinal tract are frequently slow growing, yet both symptom and disease control remain important. Treatment options include resection, systemic somatostatin analogues (SSA), and systemic peptide receptor radionuclide therapy (PRRT). Additional options for patients are needed. We have explored intralesional (IL) rose bengal disodium (PV-10), an investigational autolytic immunotherapy that can yield immunogenic cell death and disease-specific functional adaptive immunity [1-5], as a monotherapy for mNEN. This investigational drug product is also undergoing clinical development for multiple other solid tumors (e.g., cutaneous melanoma, metastatic uveal melanoma, and hepatocellular carcinoma) as both a single-agent and in combination with immune checkpoint inhibition (ICI) [6-8].

PV-10 Immuno-Oncology Cycle



This phase 1 study (protocol PV-10-NET-01, **NCT02693067**) evaluated safety, tolerability, and impact on symptoms and biochemical markers resulting from IL PV-10 administered percutaneously to hepatic lesions in patients (pts) with progressive mNEN not amenable to resection or other potentially curative therapy. Eligible lesion(s) were 1.0 – 3.9 cm in longest diameter with the amount of PV-10 administered proportional to size. Cohort 1 (n = 6 pts) received PV-10 to a single lesion per treatment cycle; Cohort 2 (n = 6) could receive injection to multiple lesions per treatment cycle. Pts could receive further PV-10 ≥6 weeks after prior injection. The primary endpoint was safety. Secondary endpoints included objective response rate (ORR) assessed by contrast enhanced CT (RECIST 1.1) and ⁶⁸Ga-DOTATATE PET, biochemical response (CgA and lymphocytes), and patient-reported outcome (assessed using the EORTC QLQ-C30 and GI.NET21 QOL instruments).

Study Participants, Drug Exposure and Adverse Events

Twelve pts were enrolled, 50% male, median age 66 yrs (range 47 – 79). Primary sites: 7 small bowel, 2 pancreas, 1 caecal, 2 unknown; grade: Gd1 = 5, Gd2 = 7. All pts had received SSA and PRRT as part of previous therapy and all had symptomatic, progressive disease. Median CgA was 1585 µg/L (range 35 – 10370) at baseline.

One lesion was injected per procedure (injection cycle) for all 12 pts; none were suitable for multiple injections per cycle. One pt received 4 sequential PV-10 injection cycles, 1 received 3 cycles, 2 received 2 cycles, and 8 received 1 cycle. As of a data cutoff of 30 April 2021, two pts remained in the active treatment phase of the study.

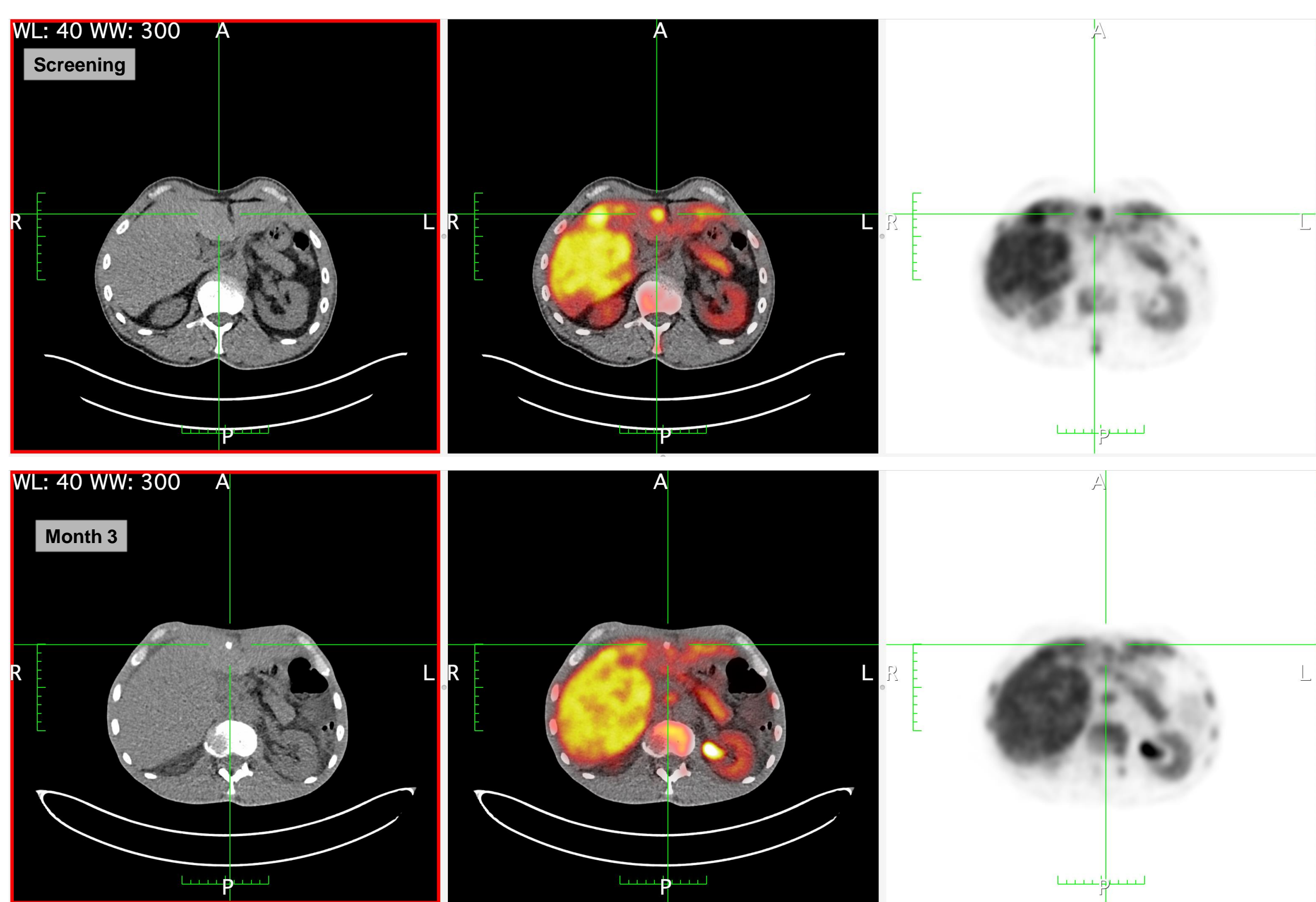
PV-10 Dose Exposure (Phase 1 ITT Population, N = 12)	Median	Mean	Range
Lesions Injected	1.0	1.6	1 – 4
Injection Cycles	1.0	1.6	1 – 4
Injected Lesion Size (cm)	1.9	2.0	1.1 – 3.2
Dose per Injection Cycle (mL)	1.9	2.5	0.5 – 8.7

Toxicity was consistent with the Sponsor's experience in other hepatic malignancies [7,9]: mild- to moderate post-procedure pain was reported by most pts; Grade 3 photosensitivity reaction occurred in 1 pt; and Grade 3 elevation of hepatic enzymes attributed to PV-10 occurred in 1 pt, resolving by Day 7. Additionally, carcinoid flare occurred in 2 pts.

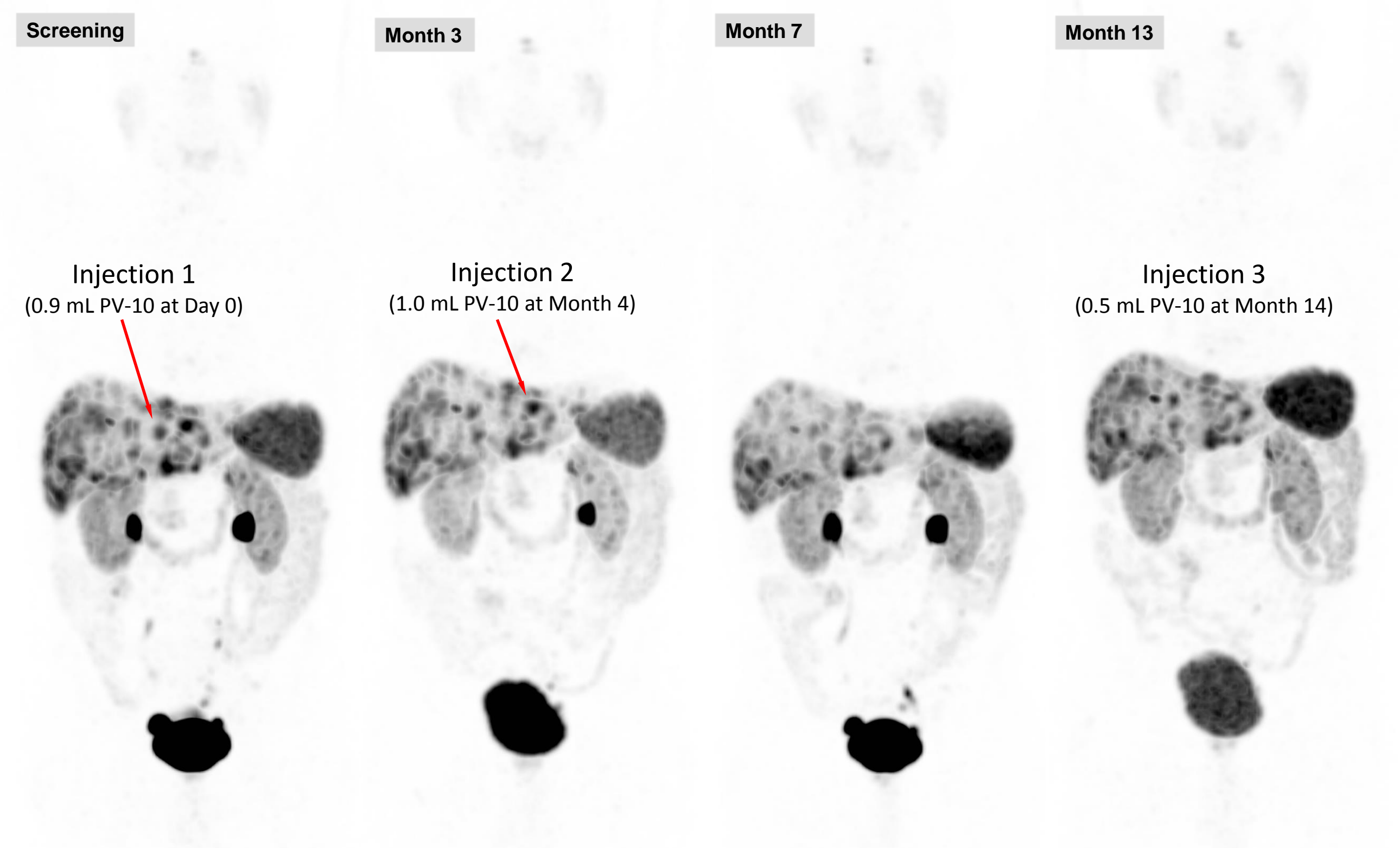
Treatment-Emergent Adverse Events (TEAEs)		TEAEs Related to PV-10	
(Phase 1 Safety Population, N = 12)		All	≥ G3
GENERAL DISORDERS AND ADMINISTRATION SITE CONDITIONS			
Injection site pain	9	0	
Flushing	4	0	
Anorexia	1	0	
Fatigue	1	0	
Pyrexia	1	0	
GASTROINTESTINAL DISORDERS			
Faeces discoloured	5	0	
Nausea	1	0	
RENAL AND URINARY DISORDERS			
Chromaturia	4	0	
SKIN AND SUBCUTANEOUS TISSUE DISORDERS			
Photosensitivity reaction	1	1	
Rash	2	0	
Purpura	1	0	
INVESTIGATIONS			
Transaminases increased	2	1	
Blood bilirubin increased	1	0	
Blood creatinine increased	1	0	
NEOPLASMS BENIGN, MALIGNANT AND UNSPECIFIED (INCL CYSTS AND POLYPS)			
Carcinoid syndrome	2	0	
INJURY, POISONING AND PROCEDURAL COMPLICATIONS			
Contusion	1	0	

AEs coded using MedDRA v24.0 for system organ class (SOC) and preferred term (PT). Subjects with more than one occurrence of the same AE are counted once based on maximum severity. All AEs deemed at least possibly related to PV-10 were Grade 1 or 2 except for single subjects experiencing Grade 3 photosensitivity reaction and transaminases increased. No subjects discontinued study participation due to a TEAE.

Example Clinical Data



Subject 0105: Male age 58, with symptomatic mNEN (diarrhea and flushing), innumerable soft tissue and bony metastases throughout abdomen and chest of small bowel origin (primary diagnosis Feb 2013); prior Rx with octreotide (SSA), lutetium Lu 177 dotatate (PRRT), and capecitabine. Single lesion injected with 1.4 mL PV-10 (Aug 2018). Fused Ga-DOTATATE PET/CT (2D orthogonal MPR) images illustrate retention of PV-10 at the injection site and reduction in metabolic activity of the injected lesion at Month 3.



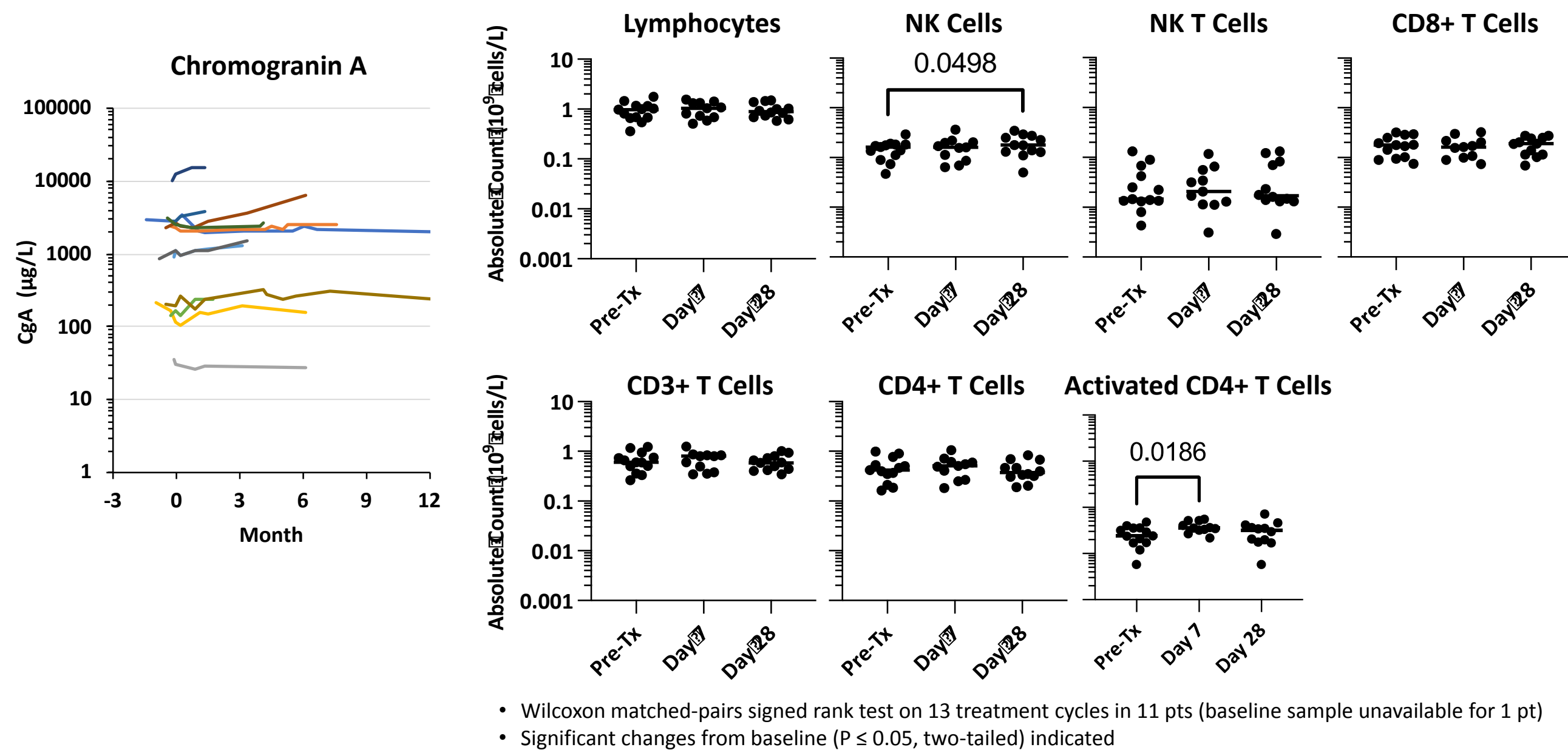
Subject 0112: Male age 75, with symptomatic mNEN (diarrhea and flushing), extensive hepatic and low volume mesenteric metastases of small bowel origin (primary diagnosis Jan 2014); prior Rx with dacarbazine, fluorouracil, octreotide, lutetium Lu 177 dotatate, lanreotide (SSA), and 5-FU. Sequential injection of 3 lesions with PV-10 at Day 0 (Jan 2020), Month 4, and Month 14. Ga-DOTATATE PET/CT (3D MIP) illustrates lasting reduction in metabolic activity of injected lesions and overall disease stabilization.

Objective Response and Correlative Assessments

ORR of injected lesions was 42% (42% PR); patient-level disease control was 84%.

Estimated median PFS (Kaplan-Meier) was 9.2 months (range 1.0 – 41.8 months); median OS was 22.5 months (range 5.5 – 41.8 months, 6 pts alive as of data cutoff).

Chromogranin A remained stable in 10 pts. Upregulation of NK (CD3-CD56+) and activated CD4+ T lymphocytes (CD3+CD56-CD4+CD25+) was observed in peripheral blood collected 7-28 days post-injection.



Quality of Life (QOL) assessments at months 1 and 3 showed stable or improved carcinoid symptoms and global health status in most pts.

QOL (Phase 1 ITT Population, N = 12)	Median	Range	Stable or Improved
Global Health Status			
Baseline (N = 12)	62.5	8.3 – 91.7	
Month 1 (N = 11)	66.7	0.0 – 100.0	8 pts
Month 3 (N = 10)	54.2	16.7 – 100.0	6 pts
Endocrine Symptoms			
Baseline (N = 12)	27.8	11.0 – 100.0	
Month 1 (N = 12)	38.9	11.1 – 55.6	8 pts
Month 3 (N = 10)	16.7	0.0 – 55.6	9 pts

Status assessed using EORTC QLQ-C30 and GI.NET21 QOL instruments. Global Health Status scored from 0 to 100 (higher is better); Endocrine Symptoms scored from 0 to 100 (lower is better). Number of pts responding at each assessment shown.

Conclusions

- PV-10 elicited no safety concerns, with encouraging evidence of both local and systemic disease and symptom control in a heavily pre-treated population.
- Multiple cycles were delivered safely.
- Adaptive immune upregulation observed in mNEN is consistent with other solid tumors [4,5,8] and supports potential systemic benefit and feasibility of combination with ICI to potentiate stronger anti-tumor immune activity in mNEN.

1. Wachter et al., SPIE 4620, 143, 2002 (lysosomal accumulation and rupture in tissue culture)
2. Thompson et al., Mel Res 18, 405, 2008 (phase 1 study of PV-10 in metastatic melanoma)
3. Toomey et al., PLoS One 8, e68561, 2013 (tumor-specific immune response in mice)
4. Liu et al., Oncotarget 7, 37893, 2016 (DAMPs, DC recruitment/activation, T-cell activation in mouse and man)
5. Qin et al., Cell Death and Disease 8, e2584, 2017 (immunogenic cell death in colon cancer)
6. Thompson et al., J Surg Oncol 22, 2135, 2015 (phase 2 study of PV-10 in metastatic melanoma)
7. Patel et al., ASCO 2020, abstract 3143 (phase 1 study of percutaneous PV-10 in metastatic uveal melanoma)
8. Agarwala et al., ESMO Virtual Congress 2020, presentation 1125P (PV-10 + pembrolizumab in checkpoint-naïve cutaneous melanoma)
9. Patel et al., SIR 2020, poster 509 (phase 1 study of percutaneous PV-10 in hepatic tumors)

Study Sponsored by: Provectus Biopharmaceuticals, Inc. Timothy Price declares no conflicts of interest.

